

Acute respiratory distress syndrome: a rare amiodarone side effect.

Syndrome de détresse respiratoire aiguë: un effet secondaire rare de l'amiodarone

Samira Mhamdi¹, Mariem Chaaben¹, Houaida Mahfoudhi², Salsabil Daboussi¹, Zied Moetamri¹, Chiraz Aichaouia¹, Islème Mejri¹, Mohsen Khadhraoui¹, Wafa Fehri², Rzaieg Cheikh¹

1 ; Pulmonology departement, military hospital. Tunis, Tunisia.

2 ; Cardiology departement, military hospital. Tunis, Tunisia

Résumé

L'amiodarone est l'un des antiarythmiques les plus connus. Cependant, il peut être responsable de plusieurs effets secondaires, notamment une toxicité thyroïdienne, hépatique, cardiaque, oculaire et pulmonaire. La toxicité pulmonaire induite par l'amiodarone est l'un des effets secondaires les plus graves. Elle survient chez environ 5 à 7% des patients recevant un traitement au long cours à base d'amiodarone (1). Cela peut entraîner une fibrose pulmonaire et même le décès si la prise en charge est retardée, en particulier chez les patients âgés souffrant d'autres comorbidités. De ce fait, les cliniciens doivent être vigilants quant à la possibilité de survenue de cette complication. Le traitement de choix consiste à arrêter la prise d'amiodarone et à prescrire un traitement systémique à base de glucocorticoïdes pour une durée de deux à six mois. Nous rapportons le cas d'une femme âgée qui a développé une détresse respiratoire aiguë après un mois d'utilisation d'amiodarone prescrit pour une fibrillation auriculaire. L'évolution était favorable sous corticostéroïde.

Mots-clés

Amiodarone, Toxicité pulmonaire, Insuffisance respiratoire aiguë, Effet indésirable.

Summary

Amiodarone is one of the most known antiarrhythmic agents. However, it can be responsible of several side effects including thyroid, hepatic, cardiac, ocular and pulmonary toxicity. Amiodarone induced pulmonary toxicity is one of the most serious side effects of using amiodarone, it occurs in approximately 5 to 7% of patients receiving long time therapy based on amiodarone (1). It can lead to pulmonary fibrosis and even death if the treatment is delayed especially with old patients suffering from other comorbidities so that clinicians must be vigilant for amiodarone-induced lung toxicity. Treatment of choice is to stop using amiodarone and administrating systemic glucocorticoid therapy during two- to six-month period. We describe a case of an old woman who developed acute pulmonary distress after a month of using amiodarone as a treatment of her atrial fibrillation and who developed a significant response to systemic corticosteroid.

Keywords

Amiodarone., pulmonary toxicity, Acute respiratory failure., Adverse effect

Correspondance

Mahfoudhi Houaida

Cardiology departement, military hospital. Tunis, Tunisia

E-mail: mahfoudhihouaida@yahoo.fr

INTRODUCTION

Amiodarone is a class III antiarrhythmic medication that is used for both supraventricular and ventricular dysrhythmias. Many side effects have been notified by using this drug especially with old patients and after a prolonged use. Amiodarone toxicity occurred in 66 of 91 patients (72.5%) treated for more than 1 week (2). Pulmonary toxicity is not the most documented but it is one of the most serious complications. Although presentation is frequently subacute or chronic, a number of acute respiratory failures are noticed with some patients. It can lead to the development of acute respiratory distress syndrome (ARDS), pulmonary fibrosis and even death if the treatment is delayed. Diagnosis may be difficult especially with patients suffering from cardiac problems.

CASE REPORT

A 85-year-old woman, presented to the emergency department complaining of shortness of breath and dyspnea at rest. Her past medical history included hypothyroidism equilibrated with treatment, bronchiectasis since 1985 and paroxysmal atrial fibrillation diagnosed a month ago and treated with amiodarone 200mg daily. The patient affirms that symptoms have appeared three weeks after using amiodarone and that she developed a limited physical activity. She was admitted to take charge of this acute respiratory failure. Physical examination showed a blood pressure 100/50 mmHg, regular pulse rate at 100 beats/min, respiratory rate 26 breaths/min and pulse saturation in oxygen at 80% on room air. Auscultation showed crackles in both lung fields heard in inspiration with no physical signs of heart failure and an electrocardiogram with sinus tachycardia. The rest of physical examination was unremarkable. The chest X-ray revealed bilateral and diffuse interstitial and alveolar opacities (Figure 1). She had a mild leukocytosis with 79% neutrophils, a normal threshold of D-dimers and

brain natriuretic peptide (BNP), blood and urine cultures were sterile. Pulmonary function tests showed restriction and pulmonary computed tomography showed aerated condensation with diffuse interstitial infiltration with bilateral pleural effusion (Figure 2). The differential diagnoses included pulmonary embolism, acute heart failure and pneumonia. Control of ventricular rate and diuresis didn't make any improvement, BNP and D-dimers were normal and cultures were sterile. So that, the most likely etiology was amiodarone-induced lung toxicity.

The treatment consisted on stopping using amiodarone, oxygen with 3 to 4 l/min with nasal cannula, and systemic corticosteroid (prednisone 1mg/kg daily). The patient showed a good response after 48hours of treatment, and was discharged home two weeks after with prednisone use over three months. Pulmonary computed tomography performed one month after, showed significant improvement of images with disappearance of pleural effusion and very important reduction of alveolo-interstitial opacities (Figure 3)

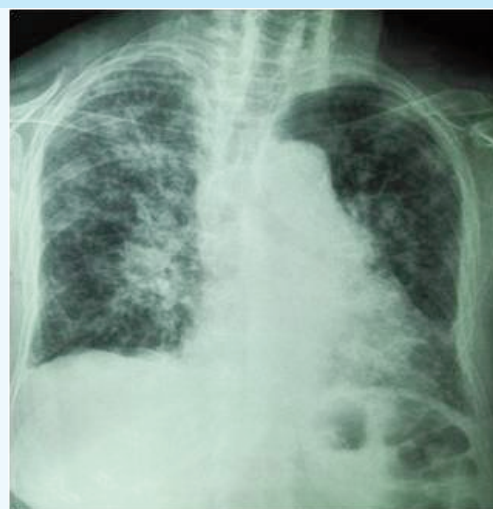

Figure 1 : Chest X-ray showing bilateral and diffuse interstitial and alveolar opacities.

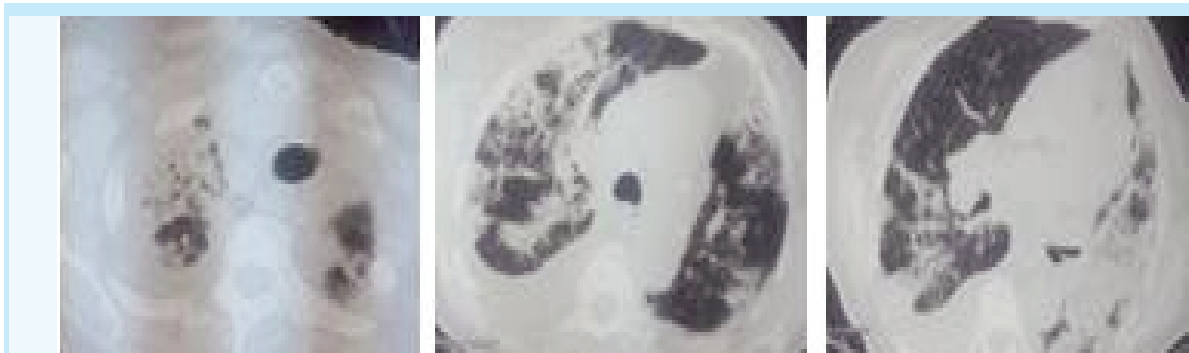


Figure 2 : Pulmonary computed tomography showing interstitial diffuse infiltration

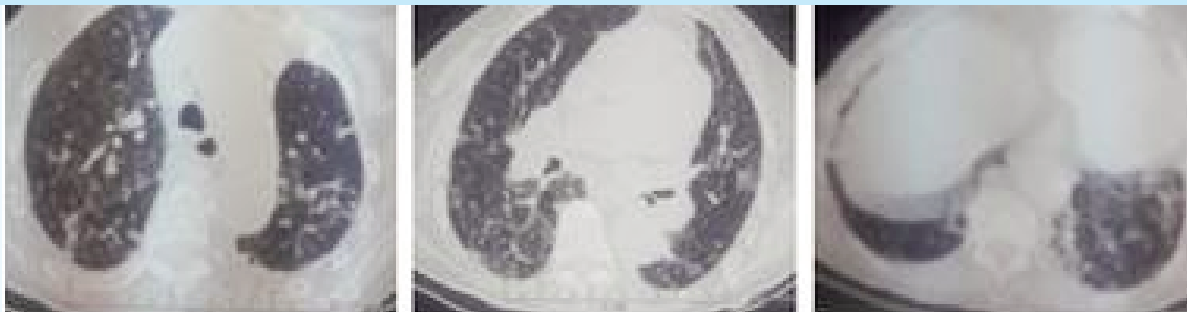

Figure 3 : Pulmonary computed tomography after one month of corticosteroids with significant improvement of images: disappearance of pleural effusion and very important reduction of alveolo-interstitial opacities

DISCUSSION

Amiodarone-induced pulmonary toxicity is often described as a result of a longtime use of high doses of amiodarone (>400mg daily) that can lead to the development of a subacute or chronic fibrosis. However, some publications have reported cases of acute respiratory failure after few weeks of treatment and with lower doses of amiodarone (3, 4, 5). Pulmonary toxicity is related to other risk factors, it has been noticed with aged patients, suffering from pre-existing lung disease, cardiac comorbidities or after cardiac surgery (4-8) with the use of intravenous amiodarone to prevent perioperative dysrhythmia (9). Many clinical presentations were described: it can be presented in a chronic form with attenuated symptoms and a slow evolution which can lead to the development of pulmonary fibrosis with chronic respiratory failure.

The clinical presentation is variable from ARDS, diffuse alveolar hemorrhage, solitary pulmonary mass to pneumonia (10, 11). For old cases reported ARDS occurs almost exclusively after thoracic surgery but in our case ARDS appeared outside a postoperative context

Other subacute cases were published with appearance of ARDS. Our case presents a rare case of acute lung toxicity after a short time of treatment with low dose of amiodarone.

The mechanism of action of amiodarone toxicity remains unknown. Amiodarone is known to inhibit phospholipase and lead to direct cell injury (12). Histological lesions included vacuoles at the level Type II alveolar epithelial cells, bronchiolar epithelium and interstitial fibroblasts. Similar vacuoles can be seen in the lymph nodes, circulating blood, liver, thyroid, GI tract and skin (13). Another theory explains that cell damage may be in part due to toxic oxygen free radicals (14). The immunological system is also implicated, indeed, in patients exhibiting amiodarone toxicity we find raised counts of polymorphonuclear leukocytes, t-suppressor and cytotoxic lymphocytes (15).

The diagnosis of amiodarone-induced lung toxicity can be difficult and can be taken as acute congestive heart failure, pulmonary embolism or pneumonia. Physical examination, cultures and biological exams can eliminate these diagnoses. The computer tomography shows an infiltrative lung disease with combined alveolar and diffuse interstitial opacities (16). Risk factors in our case include preexisting lung disease and old age (17).

When there is a strong suspicion for amiodarone-induced lung toxicity, the treatment must be started immediately. It consists on interrupting the use of amiodarone and introducing systemic corticosteroids for 3 to 6 months to attain complete recovery. It can be maintained over 12 months in some severe presentations. In our case the patient was put on steroids with a good clinical and radiological course after 1 month.

CONCLUSION

Amiodarone is a lung toxic drug that can be responsible of a chronic lung disease especially with old patients with a long time use of high cumulative doses of amiodarone. Our presentation described a rare case of acute lung toxicity with low doses of amiodarone and after only a month of starting the treatment. So that every clinician must be vigilant in front of such acute presentation that can be severe eventually if the patient is suffering from other cardiac or lung disease.

REFERENCES

1. Kay GN, Epstein AE, Kirklin JK, Diethelm A, Graybar G, Plumb V. Fatal postoperative amiodarone pulmonary toxicity. *Am J Cardiol* 1988;62:490.
2. Fogoros RN, Anderson KP, Winkle RA, Swerdlow CD, Mason JW. Amiodarone: clinical efficacy and toxicity in 96 patients with recurrent, drug-refractory arrhythmias. *Circulation* 1983;68:88-94.
3. Vorperian VR, Havighurst TC, Miller S, January CT. Adverse effects of low dose amiodarone: a meta-analysis. *J Am Coll Cardiol* 1997;30:791e8
4. Viswam D, Nair SG, Patel V. Ultra-short course of low-dose amiodarone-induced post-operative fatal pulmonary toxicity. *J. Assoc. Physicians India*. 2011; 59: 443-447.
5. Handschin AE, Lardinois D, Schneiter D, Bloch K, et al. Acute amiodarone-induced pulmonary toxicity following lung resection. *Respir Int. Rev. Thorac. Dis*. 2003; 70 (3): 310-312.
6. Kay GN, Epstein AE, Kirklin JK, Diethelm AG, et al. Fatal postoperative amiodarone pulmonary toxicity. *Am. J. Cardiol*. 1988; 62 (7): 490-492.
7. Greenspon AJ, Kidwell GA, Hurley W. Amiodarone-related postoperative adult respiratory distress syndrome. *Circulation*. 1991; 84 (5 Suppl): III407-415.
8. Saussine M, Colson P, Alauzen M, Mary H. Postoperative acute respiratory distress syndrome. A complication of amiodarone associated with 100 percent oxygen ventilation. *Chest*. 1992; 102 (3): 980-981.
9. Martin WJ, Rosenow EC. Amiodarone pulmonary toxicity. Recognition and pathogenesis (Part I). *Chest* 1988;93(5): 1067e75.10. Wolkove N, Baltzan M. Amiodarone pulmonary toxicity. *Can Respir J. J. Can Thorac Soc*. 2009; 16 (2): 43-48.
11. Schwaiblmair M, Berghaus T, Haackel T, Wagner T, et al. Amiodarone-induced pulmonary toxicity: an under-recognized and severe adverse effect? *Clin. Res. Cardiol Off J. Ger. Card Soc*. 2010; 99 (11): 693-700.
12. Zitnik RJ (1996) Drug-induced lung disease: anti-arrhythmic agents. *J Respir Dis* 17:254-269
13. Dake M, Madison JM, Montgomery CK, et al. (1985) Electron microscopic demonstration of lysosomal inclusion bodies in lung, liver, lymph nodes and blood leukocytes of patients with amiodarone pulmonary toxicity. *Am J Med* 78:506-511
14. Kay GN, Epstein AE, Kirklin JK, Diethelm AG, Graybar G, Plumb VJ (1988) Fatal postoperative amiodarone pulmonary toxicity. *Am J Cardiol* 62: 490-492
15. Martin WJ, Rosenow EC (1988) Amiodarone pulmonary toxicity; recognition and pathogenesis. *Chest* 93:1067-1075
16. Vernhet H, Bousquet C, Durand G, Giron J, Senac J. Reversible amiodarone-induced lung disease: HRCT findings. *Eur Radiol* 2001;11(9):1697e703
17. Olshansky B, Sami M, Rubin A, et al. Use of amiodarone for atrial fibrillation in patients with preexisting pulmonary disease in the AFFIRM study. *Am. J. Cardiol*. 2005; 95 (3): 404-405.