

# Ectopic thyroid tumor in the heart: the 12 year prognosis

## Tumeur thyroïdienne ectopique au niveau du cœur: pronostic à 12 ans

Sana Fennira, Boutheina Besbes, Yesmine Kammoun, Sofien Kammoun, Habib thameur\*, Mounir Dhieb\*, MA. Rejeb\*, Hela Sarray, Ihnen Zairi, Khedija Mzoughi, Sondos Kraiem

\*Service chirurgie cardiaque Clinique Montplaisir  
Service cardiologie hôpital Habib Thameur - University EL Manar2- Tunis

### Résumé

Les tumeurs cardiaques peuvent être symptomatiques, mais elles sont plus fréquemment découvertes accidentellement au cours d'un examen d'imagerie réalisé pour une indication non liée. Le tissu thyroïdien ectopique cardiaque est une anomalie rare. La probabilité de malignité dans de tels tissus est inférieure à 1%. Nous décrivons le cas d'une femme de 50 ans, sans antécédents pathologiques particuliers, qui s'est présentée avec une dyspnée. L'échocardiographie a montré une masse échogène homogène, arrondie, mesurant 36 × 27 mm de diamètre, située dans la chambre de chasse du ventriculaire droit. La tumeur a été complètement réséquée. L'examen histologique a révélé un parenchyme thyroïdien normal. Une enquête plus poussée n'a révélé aucun autre site ectopique. Après 12 ans de suivi, le patient est en bonne santé sans récurrence. En conclusion, bien que les tumeurs cardiaques soient rares, elles sont de plus en plus reconnues grâce aux techniques d'imagerie modernes.

### Mots-clés

Ectopique, Thyroïde, Tumeur, Cœur

### Summary

Cardiac tumors may be symptomatic, but they are more frequently discovered incidentally during an imaging examination performed for an unrelated indication. Cardiac ectopic thyroid tissue is a rare abnormality. The probability of malignancy in such tissue is less than 1%. We describe a case of a 50-year-old woman, with no particular pathological history, who presented with dyspnea. Echocardiography showing homogeneous, rounded, echogenic mass measuring 36 × 27 mm in diameter, located in the right ventricular outflow. The tumor was completely resected. Histological examination revealed normal thyroid parenchyma. Further investigation revealed no other ectopic sites. After 12 years of follow-up, the patient is in a good health with no recurrence. In conclusion, although cardiac tumors are rare, they are being increasingly recognized thanks to modern imagery techniques.

### Keywords

Ectopic, Thyroid, Tumor, Heart

### Correspondance

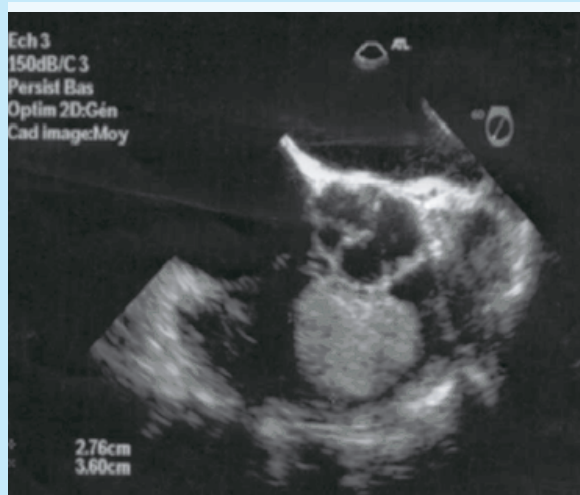
Sana Fennira,  
Associate professor,  
Habib Thameur Hospital, Tunis, Medical School of Tunis, El Manar, Tunisia.  
Mail: fennira2@yahoo.fr

## INTRODUCTION

Cardiac tumors may be symptomatic, but they are more frequently discovered incidentally during an imaging examination performed for an unrelated indication. Cardiac mass are most likely benign, with nearly 50% of likelihood of being a myxoma. Cardiac primary tumors are extremely rare with an autopsy frequency of only 0.001-0.03% [1,2]. Ectopic thyroid tissue is a rare abnormality, with a reported incidence of 1 in 300 000 [3,4]. The probability of malignancy in such tissue is less than 1%[4']. We share our experience of the successful management of a cardiac thyroid ectopic tumor.

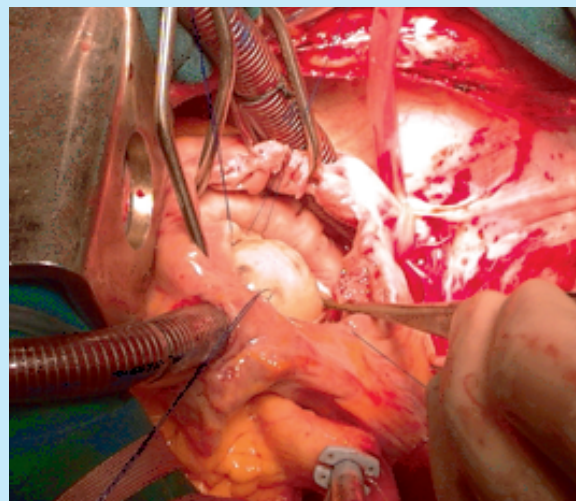
## CASE PRESENTATION

A 50-year-old woman, with no particular pathological history, consulted for recent worsening dyspnea. Physical examination was unremarkable. The electrocardiogram showed a regular sinus rhythm and a complete right bundle branch block. On the chest X-ray, the cardiac figure was normal and there were no pleuropulmonary abnormalities. Echocardiography (Fig.1) showed an homogeneous, rounded, echogenic mass measuring 36 × 27 mm in diameter, located in the right ventricular (RV) outflow and prolapsed in the pulmonary tract, thus creating an intermittent pulmonary obstruction with maximum velocity of 4.3 m/sec, maximum gradient of 80mmHg and mean gradient of 40 mmHg. There were no sonographically visible masses in the other chambers of the heart. The diagnosis of RV myxoma was most likely.

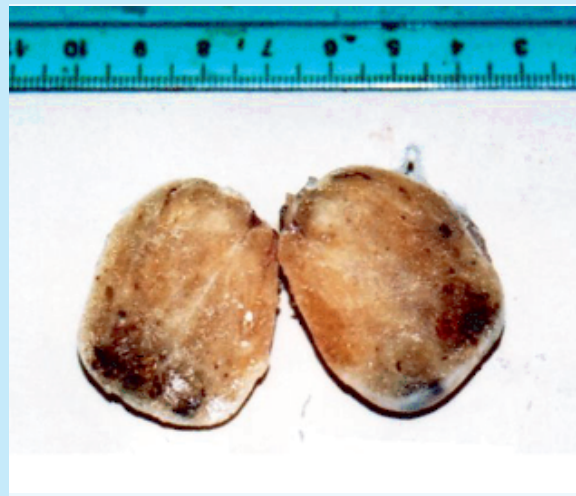


**Figure 1 :** Transesophageal ultrasound showing an homogeneous, rounded, echogenic mass measuring 36 × 27 mm in diameter, located in the right ventricular outflow resembling to a myxoma.

Surgical resection was indicated. After right atrium incision, we found that the tumor had an implantation base on the tricuspid pillar and prolapsed in the RV outflow tract. The tumor was completely resected. Macroscopically, the tumor was yellowish and spongy (Fig. 2, 3).



**Figure 2 :** Per operative view of the tumor



**Figure 3:** Macroscopic aspect of the tumor: yellowish and spongy tumor

Histological examination revealed thyroid parenchyma consisting of vesicles of variable size surrounded by regular cubic cells without papillary formation. The nodule was surrounded by a richly vascularized stroma. There were no signs of malignancy.

The thyroid gland exploration (thyroid assessment, cervical ultrasound and thyroid scintigraphy) was normal. In order to eliminate another ectopic localization of the thyroid tissue, we prescribed a brain and thoraco-abdominal CT scan, which returned normal. 12 years after surgery, the patient is in a good health with no cardiac recurrence of thyroid tissue confirmed by transesophageal echocardiography.

## DISCUSSION

The clinical presentation of cardiac masses is unspecific. It can be diagnosed studying an embolism, arrhythmias, or obstructive symptoms [5].

Primary cardiac tumours are infrequent and their incidence is around 0.05%.

In three quarters of cases, they are benign, and half of them are myxomas [1]. A metastasictumour is more frequent than a primary one [2].

Ectopic thyroid tissue is defined as that tissue not located in its normal anatomical position [3]. The most described localizations of ectopic thyroid tissue are lingual, thyroglossal and laryngotracheal. Rarely, it can be described in other sites such as the heart, the aorta and the esophagus [4]. Malignancy can occur in less than 1% of the cases. Papillary carcinomas are the most frequently described [4]. In our case, the eutopic and the ectopic thyroid tissue were normal and there was no recurrence after 12-year follow-up.

## REFERENCES

1. Xenos ES, Freeman M, Stevens S, Cassada D, Pacanowski J, Goldman M. Covered stents for injuries of subclavian and axillary arteries. *J Vasc Surg.* 2003 Sep;38(3):451-4.
2. Guilbert MC, Elkouri S, Bracco D, Corriveau MM, Beaudoin N, Dubois MJ, et al. Arterial trauma during central venous catheter insertion: Case series, review and proposed algorithm. *J Vasc Surg.* 2008 Oct;48(4):918-25; discussion 25.
3. Akyuz M, Gokalp O, Ozcem B, Ozcan S, Besir Y, Gurbuz A. Surgical management of axillosubclavian vascular injuries. *Pak J Med Sci.* 2015;31(3):552-5.
4. DuBose JJ, Rajani R, Gilani R, Arthurs ZA, Morrison JJ, Clouse WD, et al. Endovascular management of axillo-subclavian arterial injury: a review of published experience. *Injury.* 2012 Nov;43(11):1785-92.
5. du Toit DF, Strauss DC, Blaszczyk M, de Villiers R, Warren BL. Endovascular treatment of penetrating thoracic outlet arterial injuries. *Eur J Vasc Endovasc Surg.* 2000 May;19(5):489-95.
6. Ben Omrane S, Ben Hammamia M, Ben Mrad M, Kaouel K, Daoued Z, Khayati A. Traumatic dissection of the innominate artery. A case report. *J Mal Vasc.* 2014 Feb;39(1):73-6.
7. Wisborg T, Flaatten H, Koller ME. Percutaneous placement of permanent central venous catheters: experience with 200 catheters. *Acta Anaesthesiol Scand.* 1991 Jan;35(1):49-51.
8. Pikwer A, Acosta S, Kolbel T, Malina M, Sonesson B, Akeson J. Management of inadvertent arterial catheterisation associated with central venous access procedures. *Eur J Vasc Endovasc Surg.* 2009 Dec;38(6):707-14.
9. Demetriades D, Chahwan S, Gomez H, Peng R, Velmahos G, Murray J, et al. Penetrating injuries to the subclavian and axillary vessels. *J Am Coll Surg.* 1999 Mar;188(3):290-5.
10. Kalakuntla V, Patel V, Tagoe A, Weaver W. Six-year experience with management of subclavian artery injuries. *Am Surg.* 2000 Oct;66(10):927-30; discussion 30-1.
11. Kaouel K, Elleuch N, Ben Hammamia M, Ben Mrad I, Kalfat T, Khayati A. Angioplasty of the vertebral artery in Takayasu's arteritis. *Tunis Med.* 2013 Jul;91(7):478-9.
12. Patel AV, Marin ML, Veith FJ, Kerr A, Sanchez LA. Endovascular graft repair of penetrating subclavian artery injuries. *J Endovasc Surg.* 1996 Nov;3(4):382-8.
13. Leung J, Duffy M, Finckh A. Real-time ultrasonographically-guided internal jugular vein catheterization in the emergency department increases success rates and reduces complications: a randomized, prospective study. *Ann Emerg Med.* 2006 Nov;48(5):540-7.

## CONCLUSION

In conclusion, although cardiac tumors are rare, they are being increasingly recognized thanks to modern imagery techniques. The diagnosis of ectopic thyroid thyroid tumor may not be easy. Even in the presence of a normal thyroid gland, ectopic thyroid carcinoma should be considered in the differential. Fortunately, these tumors are extremely rare, less likely encountered in clinical practice.

**Acknowledgements:** The authors would like to thank the patient and her family for allowing them to publish this work.

**Funding:** None.

**Ethics approval and consent to participate:** Not applicable.

**Consent for publication:** Written informed consent was obtained from the patient for the publication of this case report and any accompanying images.