

Myocardial performance after coronary arteries reimplantation: Conventional echocardiographic, Doppler and 2D- speckle tracking analysis

Apport de l'échocardiographie après chirurgie avec réimplantation des artères coronaires : Place de l'étude des déformations myocardiques

Salma Charfeddine, Dorra Abid, Leila Abid, Rania Hammami, Samir Kammoun

Department of cardiology, HediChaker university hospital, Sfax, Tunisia

Résumé

Introduction : L'évaluation de la fonction ventriculaire gauche après la chirurgie de réimplantation des artères coronaires est un élément essentiel dans le suivi des opérés du fait qu'il conditionne le pronostic. Le 2D strain est actuellement un outil prometteur permettant de détecter d'éventuelles dysfonctions VG infra clinique.

Objectif : Etudier la fonction ventriculaire gauche chez les patients dont la chirurgie a comporté une réimplantation des artères coronaires en utilisant la méthode du 2D strain afin de dégager l'effet de la réimplantation sur l'avenir du ventricule gauche.

Méthodes : Il s'agit d'une étude type cas témoin mono-centrique qui a inclus 36 patients qui ont eu une chirurgie de correction de cardiopathies congénitales. Tous les participants ont bénéficié d'une échographie standard plus une étude de déformations myocardiques 2D strain ou speckle tracking echocardiography (STE).

Résultats : Tous les patients étaient asymptomatiques. La FeVG était supérieure à 60% chez tous les patients. L'étude 2D strain du ventricule gauche a montré une diminution du strain longitudinal global (-19.9±2.2% (groupe 1) versus -20.9±1.6% (groupe 2) versus -22.9±2.3% (groupe 3), p<0.001) ainsi du strain circonférentiel du VG. Il n'y avait pas de différence quant au strain radial du VG. Les segments concernés par cette baisse sont les segments de la paroi septale, antéro-septo-apicale, postérieure et latérale. Chez les opérés il y avait une altération de la fonction systolique du ventricule droit.

Conclusion : Bien que la fonction ventriculaire gauche paraissait normale après réimplantation des artères coronaires à l'échographie conventionnelle, l'étude par le 2D strain a permis de démasquer un début d'altération de la fonction systolique du VG qui reste infra clinique.

Mots-clés

Réimplantation des artères coronaires, Fonction ventriculaire gauche, 2D strain, Ross, Switch artériel

Summary

Background: Surgery is nowadays the treatment of choice for many cardiac heart diseases (CHD) during the neonatal period. The arterial switch operation (ASO) is the standard procedure for the repair of transposition of the great arteries (TGA). Reduced exercise capacity, coronary artery abnormalities, and reversible myocardial ischemia have been demonstrated in patients who have undergone ASO. Despite this, indices of systolic function, assessed by standard and Doppler echocardiography, are within the normal range.

Aim: To highlight the long-term changes in myocardial function following coronary reimplantation using Doppler and speckle-tracking imaging (STI) echocardiography.

Methods: We studied 36 asymptomatic patients, 21 patients were treated by coronary reimplantation (Group 1) and 15 patients had surgical correction of cardiac septal defect (Group 2). Each group was compared to 20 healthy controls (Group 3).

Results: The LV global peak strain parameters revealed a significant decrease in the longitudinal and circumferential strain components. The LV global longitudinal strain (GLS) values were lower in both groups of operated patients than controls (-19.9±2.2% (group 1) versus -20.9±1.6% (group 2) versus -22.9±2.3% (group 3), p<0.001). The patients with coronary reimplantation had the lowest values. The LV global circumferential strain was also decreased in the group 1 patients as compared with the 2 other groups (-16.6±4.1% (group 1) versus -19.4±3.9% (group 2) versus -19.8±4.0% (group 3), p<0.001).

Conclusion: Although global LV function, assessed with conventional echocardiographic parameters, was normal, the 2D-STI analysis showed slight but significant decrease in the global and segmental longitudinal and circumferential LV strain during the long-term follow-up after coronary arteries reimplantation.

Keywords

Arterial switch operation, speckle-tracking echocardiography, ventricular function

Correspondance

Salma Charfeddine

Cardiology department, Hedi Chaker University Hospital, Sfax, Tunisia

email: selma_charfeddine@yahoo.fr

INTRODUCTION

Surgery is the treatment of choice for many cardiac heart diseases (CHD) during the neonatal period. The surgical techniques most widely employed are that involving coronary arteries reimplantation.

In fact, the introduction of anatomical correction of transposition of the great arteries (TGA) with the arterial switch operation (ASO) was associated with low surgical mortality [1] and good long term survival [2]. The surgical treatment of anomalous origin of the coronary artery from the pulmonary artery (ALCAPA) involving coronary reimplantation was also reported to be the technique of choice and associated to lower short and long-term morbi-mortality [3]. The Ross procedure is accepted in the treatment of congenital aortic valve disease to avoid oral anticoagulation and to achieve potential valve growth [4].

A major concern about the outcome of the coronary reimplantation is still its repercussions on the cardiac function, which is a major prognostic factor. The long-term cardiac worsening performance has been previously reported after surgical correction of a congenital heart defect [5, 6]. However, limited and controversial data have been reported concerning the long-term cardiac function changes in patients with coronary reimplantation [3, 7, 8]. Currently, the development of echocardiographic techniques, including the tissue Doppler imaging (TDI) and the speckle tracking imaging (STI), allows a better detection of subclinical global and regional myocardial dysfunction [9, 10].

The aim of the present study, as a part of the clinical follow-up, was to highlight the long-term changes in myocardial function following coronary reimplantation using TDI and STI echocardiography.

METHODS

Study population:

A total of 36 patients were included in the study, 21 patients were treated by coronary reimplantation (Group 1) and 15 patients had surgical correction of cardiac septal defect (Group 2). Each group was compared to 20 healthy controls (Group 3). All the patients were asymptomatic at the moment of inclusion. The study was approved by a local Ethics Committee and an oral informed consent was obtained before the participation to the protocol. For all the subjects (under 18 years old of age), an oral parental consent was also obtained. Different physical parameters were recorded for all participants. The body surface area (BSA) was calculated by the Mosteller formula [11]. The 2D transthoracic echocardiography (TTE), Doppler studies and STI were also performed using a GE Vivid E9 ultrasound machine. Two-dimensional trans-thoracic echocardiographic (2D-

TTE) study:

The 2D-TTE was performed to assess biventricular performance using a commercially available system (Vivid-E9, General Electric Healthcare, Horten, Norway). Images were stored in digital format to allow off-line analyses using EchoPac. Off-line analysis was performed by one observer to limit possible interobserver variability.

Conventional echocardiographic and Doppler imaging study:

Parasternal long-axis view was used for the M-Mode measurements of left atrial diameter, interventricular septal, LV posterior wall thickness (IVST and LVPWT), LV end-diastolic and end-systolic dimensions (LVEDD and LVESD). The LV fractional shortening (LVFS) was calculated as $(LVEDD - LVESD)/LVEDD$. The LV ejection fraction (LVEF) was calculated from LV volumes by the modified biplane Simpson rule and expressed as a percentage. The pulsed Doppler transmitral flow velocity profile was obtained from the apical four-chamber view by the sample volume positioned below the mitral leaflets. Different parameters were evaluated: peak transmitral flow velocity in early diastole (E), peak transmitral flow velocity in late diastole (A), E/A ratio, and the E deceleration time (DT). The Tissue Doppler imaging (TDI) was also performed in the four-chamber view, with the mitral and tricuspid annular planes perpendicular to the ultrasound beam. Pulsed TD sample volume was placed at the septal and lateral aspects of the mitral annulus, and at the lateral aspect of the tricuspid annulus. Measurements were made of peak systolic (S'), peak early diastolic (E'), and late peak diastolic myocardial velocities (A'), and the E/E' ratio at the lateral mitral annulus. To assess the right ventricular (RV) systolic function, we also measured the peak systolic (S) velocity at the lateral tricuspid annulus and the tricuspid annular plane systolic excursion (TAPSE) as previously described [12].

Speckle tracking imaging study:

The global and regional LV function was assessed by 2D-strain, expressing as percent change in segment length. Negative values represent segmental shortening, whereas positive values represent lengthening. End diastole was defined at the peak R wave of the electrocardiographic QRS complex, and end-systole defined at aortic valve closure determined in the apical 5-chambers long-axis view. The following six views were displayed: the apical four-chamber view, the apical three-chamber view, the apical two-chamber view and the three short-axis views, the apex of the LV, the midlevel of the LV, and the basal level of the LV. The endocardial border was drawn manually and thickness of the region of interest adjusted to cover the myocardium and exclude the pericardium. Automated tracking was

performed, and, if necessary, manually corrected[8]. Longitudinal regional function was measured in all 6 wall regions of the LV. The radial and circumferential regional function was measured in the LV at the apical, mid, and basal ventricular levels[13].

Statistical analysis:

Statistical analysis was performed using Statistical Package for Social Sciences version 20.0 (SPSS, Chicago, IL, USA). Continuous variables with normal distribution were presented as the mean (standard deviation, SD). Qualitative variables were given as percent. Correlations between continuous variables were assessed using Pearson's or Spearman's correlation analysis. Differences between the individual groups were tested for significance by 1-way ANOVA and the post hoc test. Univariate analysis of the effects of each continuous variable was performed with linear regression. A p-value under 0.05 was considered as statistically significant.

RESULTS

Clinical characteristics:

A total of 21 patients who underwent surgical correction with coronary reimplantation were enrolled (Group 1). Fifteen patients had surgical closure of atrial or ventricular septal defect (Group 2) and 20 healthy controls (Group 3) were enrolled. All patients were asymptomatic and none had undergone further surgery since the initial operation. In the group 1, the average age at the moment of inclusion was 11.2±4.5 years-old. The mean follow-up duration was 8.3±3.2 years. The average age of group 2 patients was 12.3±4.4 years and the mean duration of the follow-up was 8.7±2.5 years. Demographic characteristics of all participants are summarized in Table 1. There was no difference concerning the clinical findings between the 3 study groups. A total of 14 patients underwent ASO, 6 patients underwent Ross intervention and only 1 patient presented ALCAPA. Before ASO, 12 of 14 patients underwent a balloon atrial septostomy. In 7 of 14 patients with TGA, a ventricular septal defect was closed in addition to ASO. No difference was observed in aortic crossclamp time between patients with and without coronary reimplantation. The time of cardio-pulmonary bypass (CPB) was significantly longer in patients whose surgery included coronary reimplantation. Only 4 patients had coronary angiography control, which was normal. All the patients were in sinus rhythm without conduction abnormalities.

Echocardiographic characteristics:

MM - mode and 2D echocardiographic exam:

The MM- mode and 2D- echocardiographic data are presented in Table 2. No differences were found between the 3 groups concerning the LV and LA

diameters. The LVFS and LVEF were normal in the several study groups with no statistical difference. Seven patients had trivial aortic regurgitation, 3 had mild aortic regurgitation, 5 patients had mild pulmonary regurgitation and 1 patient had moderate pulmonary regurgitation. None of the controls had aortic regurgitation. Ten patients and 8 controls had trivial mitral regurgitation.

Table 1: Demographic characteristics in the different study groups

	Group 1 (n=21)	Group 2 (n=15)	Group 3 (n=20)	Group 3 (n=20)
Age (years)	11.2±4.5	12.3±4.4	10.9±4.1	10.9±4.1
Sex (M/F)	13/8	9/6	10/10	10/10
Weight (Kg)	41.2±19	43.1±13	38.0±20	38.0±20
Height (cm)	142.6±23	151.6±25	140.4±23	140.4±23
BSA (m ²)	1.26±0.4	1.35±0.4	1.20±0.4	1.20±0.4
Follow-up duration (years)	8.3±3.2	8.7±2.5	-	-
Aortic clamp time (min)	76±34	56±22	-	-
CPB time (min)	131±50	90±26	-	-

All data are expressed by mean ± SD; M: male, F: female, BSA: body surface area, CPB: cardio-pulmonary bypass, min: minutes.

Table 2 : Comparison of the MM-mode and 2D-echocardiographic data between the different study groups

	Group 1 (n=21)	Group 2 (n=15)	Group 3 (n=20)	p- value
LVEDD (mm/m ²)	41.2±4.9	40.9±6.9	39.2±7.0	0.30
LVESD (mm/m ²)	27.1±4.2	26.0±5.4	26.0±4.5	0.42
IVSTd (mm/m ²)	6.9±1.3	7.2±0.7	7.2±2.0	0.64
IVST s (mm/m ²)	8.4±1.5	8.6±0.9	8.2±2.0	0.75
LVPWTd (mm/m ²)	6.5±1.9	7.2±1.3	7.0±1.7	0.37
LVPWTs (mm/m ²)	9.6±2.0	9.2±1.0	8.9±1.4	0.20
AoD (mm/m ²)	23.2±4.5	24.3±5.5	22.4±4.4	0.57
LAD (mm/m ²)	26.9±7.3	27.9±6.3	25.5±6.1	0.51
LVFS (%)	34.2±5.2	34.4±3.7	33.0±5.2	0.51
LVEF (%)	60.5±0.9	60.7±0.8	61.1±0.7	0.92
LAA (cm ²)	10.7±3.1	11.6±2.5	9.0±4.5	0.18

All data are expressed by mean ± SD

LAD: left atrial diameter, IVST: interventricular septal thickness, LVPWT: left ventricular posterior wall thickness, LVEDD: left ventricular end-diastolic dimension, LVESD: left ventricular end-systolic dimension, LVFS: left ventricular fractional shortening, LVEFs: left ventricular ejection fraction calculated by biplane Simpson method, AoD: aorta diameter, LAA: left atrial area.

Doppler study:

Comparison of the standard transmitral Doppler parameters yielded similar E-wave, A-wave and E/A ratio between the study groups. The deceleration E-wave time was more important in group 1 than in the two other

groups ($p = 0.02$). Comparison of TDI parameters measured from the lateral mitral annulus also demonstrated lower S' rate in the group 1 patients as compared with each group 2 and controls group ($p < 0.001$). The LV diastolic function as assessed by the mean E' velocity was also lower in the 2 patients groups comparing with controls ($p < 0.001$). But, there was no difference in the E' velocity and E/E' ration between group 1 and group 2 (Table 3). Both parameters describing RV systolic performance, including RV S' and TAPSE were impaired in the operated patients. The RV S' velocity and the TAPSE were more decreased in the group of patients operated with coronary reimplantation than in the 2 other groups (Table 3).

Speckle Tracking imaging:

The LV global peak strain parameters revealed a significant decrease in the longitudinal and circumferential strain components. The LV global longitudinal strain (GLS) values were lower in both groups of operated patients than controls ($-19.9 \pm 2.2\%$ (group 1) versus $-20.9 \pm 1.6\%$ (group 2) versus $-22.9 \pm 2.3\%$ (group 3), $p < 0.001$). The patients with coronary

reimplantation had the lowest values. But, there was no difference between the 2 groups of operated patients with or without coronary reimplantation (Table 4). The LV global circumferential strain was also decreased in the group 1 patients as compared with the 2 other groups ($-16.6 \pm 4.1\%$ (group 1) versus $-19.4 \pm 3.9\%$ (group 2) versus $-19.8 \pm 4.0\%$ (group 3), $p < 0.001$). The LV GCS values were similar between the patients operated for cardiac septal defect and controls (Table 4). The LV global radial strain (GRS) was also similar in the different study groups (Table 4).

In addition to global peak strain parameters, segmental peak strain parameters were compared in patients versus controls. After coronary reimplantation, the longitudinal strain was significantly decreased in the posterior, lateral and anteroseptal walls as compared with the other patients and controls (posterior: $-17.34 \pm 2.4\%$ (group 1) versus $-20.77 \pm 2.6\%$ (group 2) versus $-25.42 \pm 2.3\%$ (group 3); lateral: $-15.65 \pm 2.2\%$ (group 1) versus $-21.36 \pm 1.9\%$ (group 2) versus $-22.32 \pm 2.1\%$ (group 3); anteroseptal: $-18.71 \pm 3.1\%$ (group 1) versus $-22.07 \pm 2.6\%$ (group 2) versus $-22.91 \pm 2.2\%$ (group 3); all $p < 0.001$).

Table 3 : Comparison of the Doppler parameters of the LV and the RV between the different study groups

	Group 1 (n=21)	Group 2 (n=15)	Group 3 (n=20)	p- value	p (group 1 vs 2)	p (group 1 vs 3)	p (group 2 vs 3)
	Mitral inflow	Mitral inflow	Mitral inflow	0.92			
E (cm/s)	103.2±17.7	105.6±20.1	104.3±15.6	0.59	NS	NS	NS
A (cm/s)	60.1±14.1	60.6±20.9	65.0±15.0	0.31	NS	NS	NS
E/A	1.76±0.3	1.79±0.2	1.64±0.2	0.02	NS	NS	NS
DT (ms)	202.0±46	183.0±29	168.0±37		NS	0.02	NS
	TDI in the mitral annulus	TDI in the mitral annulus	TDI in the mitral annulus				
Lateral S' (cm/s)	8.6±1.3	11.5±1.9	11.6±1.9	<0.001	<0.001	<0.001	NS
Septal S' (cm/s)	10.6±1.3	8.5±1.3	9.7±1.4	0.76	NS	NS	NS
E' (cm/s)	16.3±3.0	16.4±2.5	21.5±3.1	<0.001	NS	<0.001	<0.001
E/E'	6.5±2.1	6.5±1.9	4.89±0.7	0.004	NS	0.01	0.02
	RV systolic function	RV systolic function	RV systolic function				
S' Tricuspid annulus (cm/s)	8.4±1.6	10.7±1.1	14.3±1.3	<0.001	<0.001	<0.001	<0.001
TAPSE (mm)	14.8±1.9	17.6±2.3	20.5±2.7	<0.001	0.004	<0.001	0.004

All data are expressed by mean ± SD

Table 4 : Comparison of the LV global strain parameters between the different study groups

	Group 1 (n=21)	Group 2 (n=15)	Group 3 (n=20)	p	p (Group 1 vs Group 2)	p (Group 1 vs Group 3)	p (Group 2 vs Group 3)
GLS	-19.9±2.2	-20.9±1.6	-22.9±2.3	<0.001	NS	<0.001	0.01
GCS	-16.6±4.1	-19.4±3.9	-19.8±4.0	<0.001	<0.001	<0.001	NS
GRS	34.0±16.2	36.8±14.1	37.0±19.7	NS	NS	NS	NS

All data are expressed by mean ± SD

(Figure 1). There was no significant difference in the other LV walls. The longitudinal strain values from all 6 LV wall regions were averaged for basal, mid, and apical levels. In patients, longitudinal strain was slightly decreased at all ventricular levels, most pronounced at the basal level (Figure 2). The all LV levels strain values was notably the most decreased after coronary reimplantation (Figure 2).

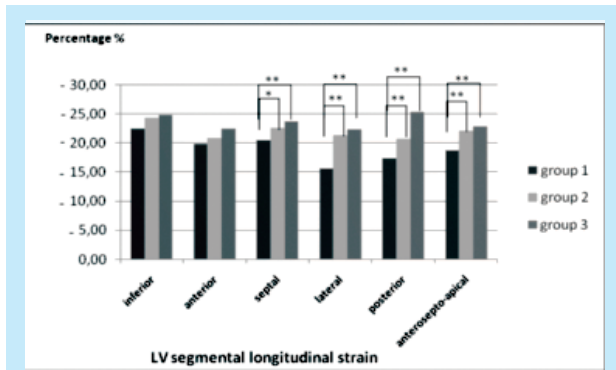


Figure 1 : Segmental longitudinal strain in the different LV walls

** p < 0.01, * p < 0.05

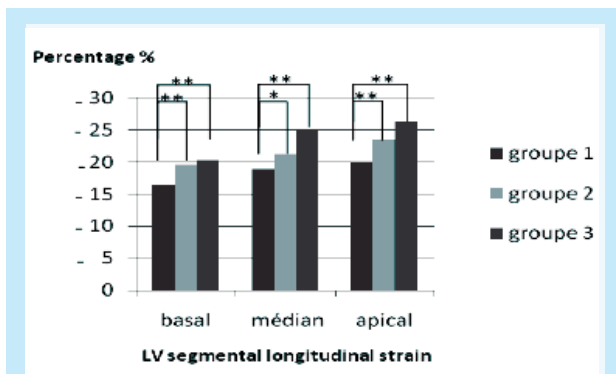


Figure 2: Segmental longitudinal strain in the different LV levels

** p < 0.01, * p < 0.05

A significant correlation was observed between the aortic cross clamp time and the LV GLS at the long-term

follow-up ($p = 0.03$ and $r = 0.42$). There were also significant correlations between the lateral LV S' velocity and the LV GLS ($p = 0.01$ and $r = -0.34$) and the diastolic LV function parameters (E' , DT and E/E') and the LV GLS. Correlations between LV GLS and clinical and echocardiographic findings are summarized in table 5. Finally, the age at operation, the CPB time and the aortic cross clamp time were not correlated to the RV performance parameters at the long-term follow-up.

DISCUSSION

In this present study, the operated patients with coronary reimplantation presented a slight but significant decrease in the LV GLS and the LV GCS at the long-term follow-up as compared with each group of operated patients for isolated cardiac septal defect and controls. The segmental longitudinal strain was decreased in all LV walls at the long-term follow-up after cardiac surgery. This decrease was more pronounced after coronary reimplantation and reached preferably the posterior, lateral and anteroapical LV walls and the basal levels. This was not revealed by the conventional LV function parameters (LV EF and LV FS), which were within the normal range values in the different groups of the study population. The LV diastolic function was also normal, except for DT and E' velocity, which were significantly decreased in the patients. Thereby, the assessment of myocardial deformation by the STI may contribute to early detection of subclinical LV impairment in the follow-up of these patients. In addition, the RV systolic function remained impaired during the follow-up. The data describing the long-term cardiac performance changes after coronary reimplantation and cardiac septal defects surgery are quite limited and the echocardiographic findings are still conflicting. Although asymptomatic, the follow-up of patients with coronary reimplantation, TGA after ASO and Ross intervention, is still characterized by decreased exercise capacity, peak VO_2 [14, 15]. Hemodynamic restrictions, including perfusion defects, reduced myocardial blood flow and coronary reserve [4] and then impaired cardiac performance [7], could add to this. Similar to our findings, Pettersen et al. [8] in a study about 22 patients with TGA reported a slight decrease in the LV longitudinal shortening as compared with healthy controls. Although standard measurements of global systolic LV function were normal in patients with TGA,

Table 5: Comparison of the LV global strain parameters between the different study groups

	CPB time	Aortic cross clamp time	Age at the surgery	LV S'	E'	E/E'	DT	TAPSE	RV S'
r	0.38	0.42	0.16	-0.34	-0.50	0.27	0.39	-0.36	-0.52
p	0.05	0.03	0.46	0.01	<0.001	0.04	0.002	0.006	<0.001

the longitudinal strain was decreased in all ventricular regions and most marked in the apical segments. Klitsie et al.[7] showed that there was no difference concerning the LV performance during the mid-term follow-up between TGA group and controls. The authors reported that the LV function recovered to the normal values within the first postoperative year if early ASO is performed. In contrast, the RV systolic and diastolic function remained impaired during the follow-up. A recent study by Di-Salvo et al.[16] demonstrated a significant decline in the longitudinal myocardial deformation, despite a normal LV ejection fraction, in a largeseries of 62 asymptomatic ASO patients by using STI. The segmental longitudinal deformation was significantly impaired in the anterior and both anterior and posterior septal walls. However, the global circumferential strain and LV torsion were similar to controls[16]. In this population, the reduction of longitudinal strain was significantly correlated with the age at surgical repair[16]. Grotenhuis et al.[17] also demonstrated decreased global systolic LV function by magnetic resonance imaging at 16-year follow-up after ASO, suggesting that our findings, such as previous studies, might represent a slight beginning dysfunction that eventually may become apparent by standard measurements of the LV function.

The echocardiographic data during the long-term follow-up in patients with atrial and ventricular septal defects (ASD, VSD) are also still controversial. Several previous studies reported a decrease in the cardiac performance immediately after surgery and a varying degree of the LV function recovery[5]. After ASD surgery, studies describing long-term follow-up, using the TDI velocities, generally reported complete recovery of the LV performance to the normal range values [18]. One previous study, which used TDI-derived LV strain and strain rate measurements, reported aregional impairment in the LV longitudinal performance in all the studied segments that persist after the first postoperative year [19]. Furthermore, the RV function, as assessed using both TDI and strain imaging, was still impaired several years after surgical ASD closure[18, 19]. After VSD surgery, several studies had reported an immediate postoperative decrease in the LV systolic and diastolic performance[20-22] and a progressive recovery to normal values during the follow-up[23]. Studies describing more long-term follow-up of ventricular function in VSD patients are limited. A previous study described decreased LV S' and E' 11 years after surgery[24]. Another study reported persistent global and regional LV strain after surgical repair of multiple VSD and the impairment was proportional to the patch repair area[25]. As in ASD patients, decreased RV systolic function was observed in VSD patients immediately after surgery[23, 26]. The alteration of the LV longitudinal deformation after coronary reimplantation could be

multifactorial. The ischemia and then the myocardial dysfunction could result from surgical repair involving coronary reimplantation and circulatory arrest. Previous studies have reported a reduced flow reserve that could alter the myocardial perfusion and the cardiac contraction [4, 27]. Furthermore, ischemia might be the result of a hypoplastic left anterior descending coronary artery, which have been described in many patients TGA[4]. Because of the abnormal LV strain values in the 2 different groups of operated patients, we could also speculate that the cardiac surgical procedure itself might alter the cardiac performance. In addition, the decrease in the LV longitudinal strain might be due to differences in the myocardial architecture between patients and controls [8]. In fact, the potential differences in fiber structure at the base might be due to the altered relation between the ventricular outlet parts [8]. Our study support this hypothesis, as it demonstrated that decrease was most pronounced at the basal levels. We have also demonstrated that although the reduction in the LV strain might be due in part to the open-heart surgery, the coronary reimplantation was associated with a marked LV strain impairment, suggesting additional adverse mechanisms that could not be totally elucidated. Thereby, these patients could be closely monitored. Finally, our findings were concordant with the previous one that yielded persistent RV dysfunction after cardiac surgery. We also demonstrated that the RV systolic decrease was more marked after coronary reimplantation. The precise mechanism could not be totally elucidated. In fact, the RV persistent impairment might be attributable to different causes, such as the surgical trauma, durable hypoxia [28], ischemic and inflammatory cascades secondary to incomplete myocardial protection and cardio-pulmonary bypass [29] or the damage of the coronary arteries[8]. Despite previous studies reported significant correlation between the postoperative RV performance and the CPB and the aortic crossclamp time [30], there was no correlation in the present study.

Study limitations:

- A limitation for our study was the relatively low case number of each group.
- The finding of decreased longitudinal strain should be correlated to coronary angiographic findings. Yet, coronary angiography was not clinically indicated for all patients and was thus made impossible for ethical reasons.
- We only used 2D STI analysis, whereas, it was recently reported the added value of 3D strain.
- The finding of STI analysis could be, ideally, correlated to the MRI findings. But, MRI is expensive and not always available for routine monitoring.

CONCLUSIONS

Although global LV function, assessed with conventional echocardiographic parameters, was normal, the 2D-STI analysis showed slight but significant decrease in the global and segmental longitudinal and circumferential LV strain during the long-term follow-up of different CHD patients. The strain decrease was more pronounced after coronary reimplantation. The RV systolic function remained also impaired in these patients during the follow-up. These findings highlight the importance of long-term follow-up after CHD surgery and especially if associated with coronary reimplantation.

Practical implications:

The present results highlight the importance of the echocardiographic study during long-term follow-up after cardiac surgery to detect slight changes in the biventricular function even in asymptomatic patients. The conventional echocardiography can detect some

differences after coronary reimplantation but it is incapable to reveal differences in intrinsic myocardial functions. Thereby, the evaluation of STI can be useful for identifying previously undetected differences in these patients. The present study showed a lower LV global and segmental longitudinal and circumferential strain after coronary reimplantation as compared with cardiac surgery for isolated septal defects and healthy controls.

Considering our results and the large heterogeneity of echocardiographic pattern generally found in operated CHD, several possible clinical applications of deformation parameters approach can be advised.

Conflict of interest:

The authors declared no potential conflicts of interest with respect to the research, authorship, and/or publication of this article.

REFERENCES

- Sarris GE, Chatzis AC, Giannopoulos NM, Kirvassilis G, Berggren H, Hazekamp M, et al. The arterial switch operation in Europe for transposition of the great arteries: a multi-institutional study from the European Congenital Heart Surgeons Association. *J Thorac Cardiovasc Surg.* sept 2006;132(3):633-9.
- Lalezari S, Bruggemans EF, Blom NA, Hazekamp MG. Thirty-year experience with the arterial switch operation. *Ann Thorac Surg.* sept 2011;92(3):973-9.
- Ramírez S, Curi-Curi PJ, Calderón-Colmenero J, García J, Britton C, Erdmenger J, et al. Outcomes of Coronary Reimplantation for Correction of Anomalous Origin of Left Coronary Artery From Pulmonary Artery. *Rev Esp Cardiol Engl Ed.* août 2011;64(8):681-7.
- Hauser M, Bengel FM, Kühn A, Sauer U, Zylla S, Braun SL, et al. Myocardial blood flow and flow reserve after coronary reimplantation in patients after arterial switch and ross operation. *Circulation.* 10 avr 2001;103(14):1875-80.
- Klitsie LM, Roest AAW, Blom NA, ten Harkel ADJ. Ventricular performance after surgery for a congenital heart defect as assessed using advanced echocardiography: from doppler flow to 3D echocardiography and speckle-tracking strain imaging. *Pediatr Cardiol.* janv 2014;35(1):3-15.
- Klitsie LM, Kuipers IM, Roest AAW, Van der Hulst AE, Stijnen T, Hazekamp MG, et al. Disparity in right vs left ventricular recovery during follow-up after ventricular septal defect correction in children. *Eur J Cardio-Thorac Surg Off J Eur Assoc Cardio-Thorac Surg.* août 2013;44(2):269-74.
- Klitsie LM, Roest AAW, Kuipers IM, Hazekamp MG, Blom NA, Ten Harkel ADJ. Left and right ventricular performance after arterial switch operation. *J Thorac Cardiovasc Surg.* mai 2014;147(5):1561-7.
- Pettersen E, Fredriksen P-M, Urheim S, Thaulow E, Smith H-J, Smevik B, et al. Ventricular function in patients with transposition of the great arteries operated with arterial switch. *Am J Cardiol.* 15 août 2009;104(4):583-9.
- Cho G-Y, Chan J, Leano R, Strudwick M, Marwick TH. Comparison of two-dimensional speckle and tissue velocity based strain and validation with harmonic phase magnetic resonance imaging. *Am J Cardiol.* 1 juin 2006;97(11):1661-6.
- Marcucci C, Lauer R, Mahajan A. New echocardiographic techniques for evaluating left ventricular myocardial function. *Semin Cardiothorac Vasc Anesth.* déc 2008;12(4):228-47.
- Mosteller RD. Simplified calculation of body-surface area. *N Engl J Med.* 22 oct 1987;317(17):1098.
- López-Candales A, Rajagopalan N, Gulyasy B, Edelman K, Bazaz R. Comparative echocardiographic analysis of mitral and tricuspid annular motion: differences explained with proposed anatomic-structural correlates. *Echocardiogr Mt Kisco N. avr 2007;24(4):353-9.*
- Klitsie LM, Roest AAW, van der Hulst AE, Stijnen T, Blom NA, Ten Harkel ADJ. Assessment of intraventricular time differences in healthy children using two-dimensional speckle-tracking echocardiography. *J Am Soc Echocardiogr Off Publ Am Soc Echocardiogr.* juin 2013;26(6):629-39.
- Giardini A, Khambadkone S, Rizzo N, Riley G, Pace Napoleone C, Muthialu N, et al. Determinants of exercise capacity after arterial switch operation for transposition of the great arteries. *Am J Cardiol.* 1 oct 2009;104(7):1007-12.
- de Koning WB, van Osch-Gevers M, Ten Harkel ADJ, van Domburg RT, Spijkerboer AW, Utens EMWJ, et al. Follow-up outcomes 10 years after arterial switch operation for transposition of the great arteries: comparison of cardiological health status and health-related quality of life to those of the a normal reference population. *Eur J Pediatr.* sept 2008;167(9):995-1004.
- Di Salvo G, Bulbul ZA, Issa Z, Fadel B, Al-Sehly A, Pergola V, et al. Left ventricular mechanics after arterial switch operation: a speckle-tracking echocardiography study. *J Cardiovasc Med Hagerstown Md.* mars 2016;17(3):217-24.

17. Grotenhuis HB, Ottenkamp J, Fontein D, Vliegen HW, Westenberg JJM, Kroft LJM, et al. Aortic elasticity and left ventricular function after arterial switch operation: MR imaging--initial experience. *Radiology*. déc 2008;249(3):801-9.
18. Cheung Y, Lun K, Chau AKT. Doppler tissue imaging analysis of ventricular function after surgical and transcatheter closure of atrial septal defect. *Am J Cardiol*. 1 févr 2004;93(3):375-8.
19. Di Salvo G, Drago M, Pacileo G, Carrozza M, Santoro G, Bigazzi MC, et al. Comparison of strain rate imaging for quantitative evaluation of regional left and right ventricular function after surgical versus percutaneous closure of atrial septal defect. *Am J Cardiol*. 15 juill 2005;96(2):299-302.
20. Cheung MMH, Smallhorn JF, Vogel M, Van Arsdell G, Redington AN. Disruption of the ventricular myocardial force-frequency relationship after cardiac surgery in children: noninvasive assessment by means of tissue Doppler imaging. *J Thorac Cardiovasc Surg*. mars 2006;131(3):625-31.
21. Quinn TA, Cabreriza SE, Blumenthal BF, Printz BF, Altmann K, Glickstein JS, et al. Regional functional depression immediately after ventricular septal defect closure. *J Am Soc Echocardiogr Off Publ Am Soc Echocardiogr*. oct 2004;17(10):1066-72.
22. Vassalos A, Lilley S, Young D, Peng E, MacArthur K, Pollock J, et al. Tissue Doppler imaging following paediatric cardiac surgery: early patterns of change and relationship to outcome. *Interact Cardiovasc Thorac Surg*. août 2009;9(2):173-7.
23. Baghdady Y, Kamel Y, Amar W. Myocardial performance index after surgical correction of ventricular septal defects. *Arch Med Sci AMS*. 30 juin 2010;6(3):328-35.
24. Pedersen TAL, Andersen NH, Knudsen MR, Christensen TD, Sørensen KE, Hjortdal VE. The effects of surgically induced right bundle branch block on left ventricular function after closure of the ventricular septal defect. *Cardiol Young*. août 2008;18(4):430-6.
25. Matsuhisa H, Yoshimura N, Higuma T, Misaki T, Onuma Y, Ichida F, et al. Ventricular septal dysfunction after surgical closure of multiple ventricular septal defects. *Ann Thorac Surg*. sept 2013;96(3):891-7.
26. Zacharska-Kokot E. The myocardial performance index in children after surgical correction of congenital malformations with intracardiac shunt. *Kardiol Pol*. févr 2007;65(2):143-50; discussion 151-2.
27. Hui L, Chau AKT, Leung MP, Chiu CSW, Cheung YF. Assessment of left ventricular function long term after arterial switch operation for transposition of the great arteries by dobutamine stress echocardiography. *Heart Br Card Soc*. janv 2005;91(1):68-72.
28. Corno AF, Milano G, Samaja M, Tozzi P, von Segesser LK. Chronic hypoxia: a model for cyanotic congenital heart defects. *J Thorac Cardiovasc Surg*. juill 2002;124(1):105-12.
29. Schuurung MJ, Bolmers PPM, Mulder BJM, de Bruin-Bon RACM, Koolbergen DR, Hazekamp MG, et al. Right ventricular function declines after cardiac surgery in adult patients with congenital heart disease. *Int J Cardiovasc Imaging*. avr 2012;28(4):755-62.
30. Klitsie LM, Hazekamp MG, Roest AAW, Van der Hulst AE, Gesink-van der Veer BJ, Kuipers IM, et al. Tissue Doppler imaging detects impaired biventricular performance shortly after congenital heart defect surgery. *Pediatr Cardiol*. mars 2013;34(3):630-8.