

Acute myocardial infarction induced by a blunt chest trauma

Infarctus aigu du myocarde dans les suites d'un traumatisme fermé du thorax

Khadija Mzoughi¹, Walid Jomaa², Hraiech A², Azaiez MA², Ben Hamda Khaldoun², Faouzi Maatouk².

¹ Cardiology Department, Habib Thameur Hospital, Tunis.

² Cardiology B Department, Fattouma Bourguiba Hospital, Monastir

Résumé

Les traumatismes thoraciques peuvent causer plusieurs formes de lésions cardiaques, dont l'infarctus aigu du myocarde (IDM). Cette complication est rare. Nous rapportons le cas d'un homme de 30 ans admis pour un IDM antérieur suite à un traumatisme fermé du thorax. Il a eu une angioplastie primaire avec désobstruction d'une occlusion thrombotique de l'interventriculaire antérieure.

Mots-clés

Infarctus aigu du myocarde, traumatisme thoracique fermé, angioplastie primaire

Summary

Blunt chest trauma can cause several forms of heart injuries, of which acute myocardial infarction (AMI) is recognized as a rare complication. We report a case of a 30-year-old man presenting with an anterior AMI following a blunt chest trauma who underwent a primary percutaneous coronary intervention with stenting of a proximal thrombotic occlusion of the left anterior descending artery.

Keywords

Acute myocardial infarction, blunt chest trauma, percutaneous coronary intervention

Correspondance

Khadija Mzoughi

Service de cardiologie, Hôpital Habib Thameur, Tunis

khadijamzoughi@yahoo.com

The occurrence of acute myocardial infarction after blunt chest trauma (BCT) is rare [1,2]. Several cases of BCT induced MI have been reported over the world in the decade [3-8]. We report the case of a 30-year-old male admitted for an AMI induced by blunt chest trauma.

CASE REPORT

A 30-year-old male was hit with a rod on the anterior chest. Eight hours after this, he presented to the emergency department for chest pain and shortness of breath. He had no history of hypertension, diabetes, nor family history of coronary artery disease. He was a regular smoker.

Physical examination noticed a normal blood pressure and heart rate was 100 beats per minute. Ecchymosis over the anterior chest wall and his left arm were noted. An electrocardiogram showed a sinus rhythm with Q waves on precordial leads and reciprocal ST segment depression in inferior leads (Fig.1).

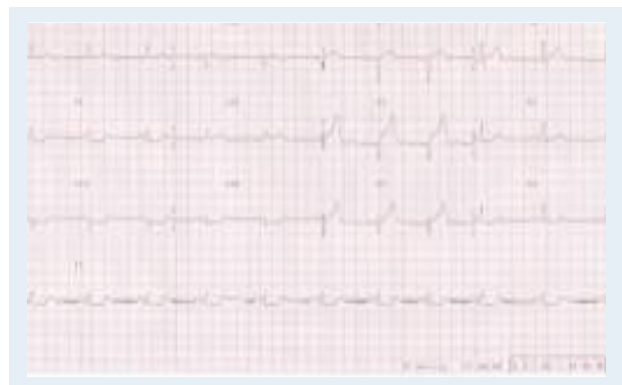

Figure 1: Electrocardiogram showed Q wave formation in V1 and V2 and a convex ST segment elevation from V1 to V6, DI and AVL and reciprocal ST segment depression in leads II, III, and AVF.

Chest radiography revealed pulmonary congestion and multiple fractures in bilateral ribs (Fig.2). Transthoracic echocardiography demonstrated severe hypokinesia of the antero-septal wall of the left ventricle with reduced left ventricular ejection fraction (LVEF= 39%) and no pericardial effusion.

He was given 500 mg of aspirin, 50 mg of heparin and 600 mg of Clopidogrel and underwent emergency cardiac catheterization. Coronary angiography revealed a thrombotic occlusion of the proximal left anterior descending (LAD) artery (Fig.3). The right coronary artery (Fig.4) and the left circumflex artery were normal. The totally occluded LAD was easily crossed by a 0.014 guide wire and dilated with a 1.5 x 20 mm balloon catheter at 10 atm resulting in TIMI 1flow and visualization of a great residual thrombus which was responsible of an immediate reocclusion (Fig.5).

Following this, the lesion was redilated with a 2.5 x 20 mm balloon catheter at 14 atm and a Duraflex® stent 3.5 x 18 mm stent was deployed in the LAD at a pressure of 12 atm, resulting in TIMI 2 flow (Figure 6,7). Then the patient was given intracoronary Verapamil (300 mg). Final angiogram showed a good result with TIMI 3 flow and without residual stenosis (Fig.8). The chest pain settled. The peak of CPK was 10 988 IU/l four hours later. There were neither arrhythmias nor conduction disturbances during admission. He was discharged asymptotically and received clopidogrel, aspirin, captopril, spironolactone and metoprolol.

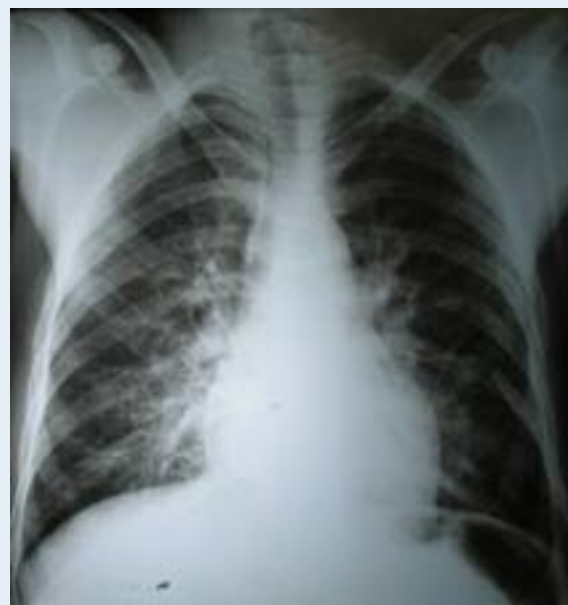

Figure 2 : Chest radiography revealed pulmonary congestion and multiple fractures in bilateral ribs.

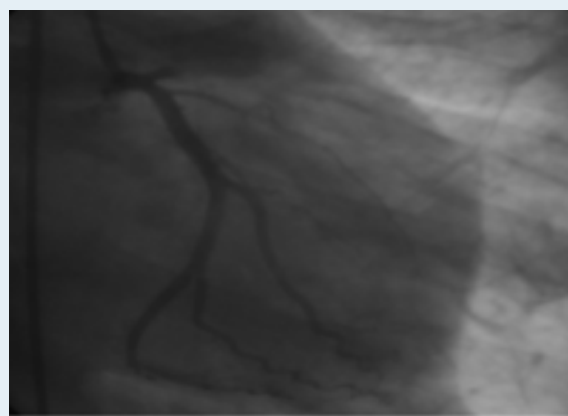


Figure 3 : Thrombotic occlusion of the proximal LAD artery.

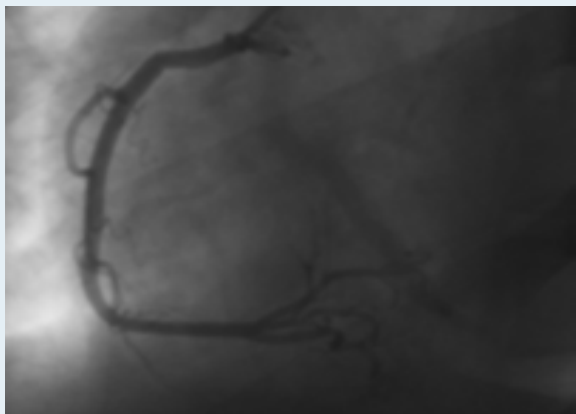


Figure 4 : Normal right coronary artery

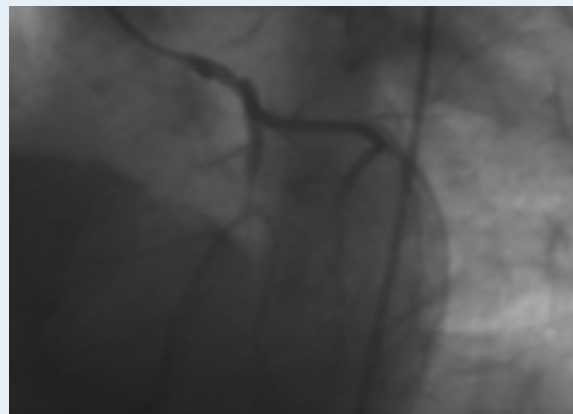


Figure 7 : Residual thrombotic stenosis of the LAD, TIMI flow 2

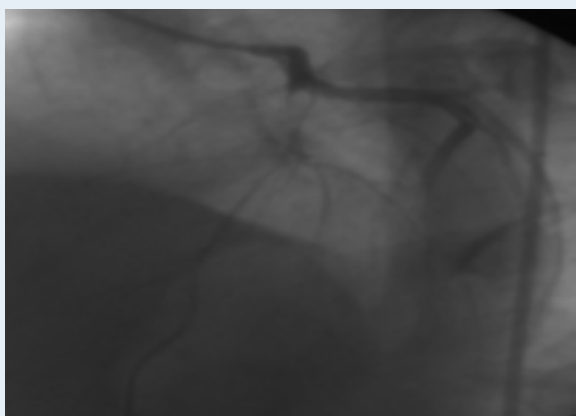


Figure 5 : Balloon angioplasty with a TIMI 1 flow and visualization of a great residual thrombus.

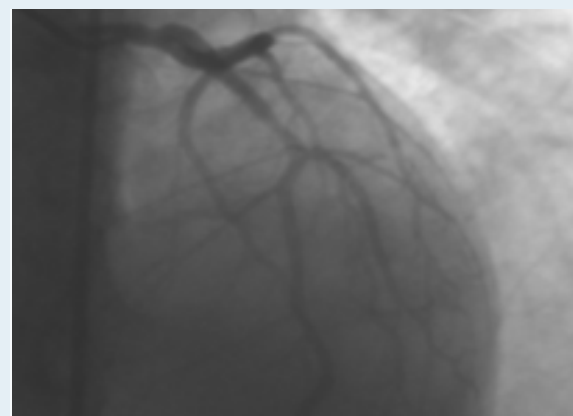


Figure 8 : Final result, TIMI flow 3.

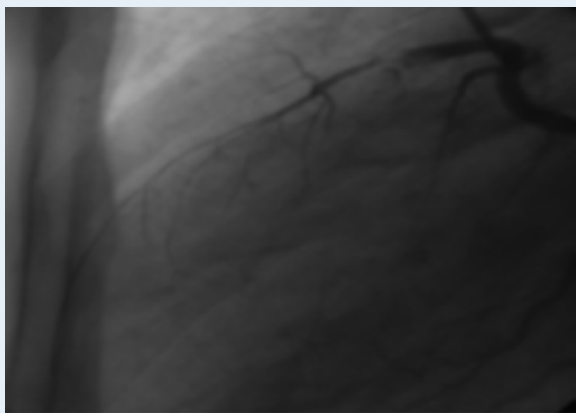


Figure 6 : Thrombus of the proximal LAD and TIMI flow 2.

DISCUSSION

Blunt trauma to the chest may result in various cardiac injuries. Injuries to the coronary artery are rare, but they can significantly increase the risk of mortality from AMI.

The proposed causes of an AMI following a blunt chest trauma include a variety of injuries to the coronary arteries, such as laceration, thrombosis, intimal dissection, arteriovenous fistula and pseudoaneurysm. Thrombosis is the main suspect in the pathogenesis of a coronary occlusion following trauma.

The mechanism leading to a myocardial infarction after a blunt chest trauma is a shear force applied to the coronary artery, which causes intimal tearing. The intimal injury in turn precipitates platelet aggregation and an intracoronary thrombosis. Compression of the anterior chest wall and the shear forces in the arterial

wall generated by the sudden deceleration during impact are presumed to be for the cause of arterial injury.

The LAD is the most frequently injured, followed by the right coronary, and the circumflex artery being the least involving lesion. The higher incidence of a LAD artery involvement may be due to its proximity to the chest wall. The possibility that preexisting atherosclerotic plaque may predispose the vessel wall to a traumatic disruption at that site has been suggested.

CONCLUSION

When patients with chest trauma have symptoms and electrocardiographic changes suggesting an AMI, immediate coronary angiography should be considered. In fact, the thrombolytic therapy is contentious because it increases the risk of hemorrhage. Further management may depend on the angiographic findings. Emergency coronary artery bypass surgery has been reported to have good results in some adequate cases, but such a major operation can be accompanied by much higher risk of post-operative complications in multiple traumatic patients. This suggests that AMI caused by blunt chest trauma may be optimally treated by direct coronary angioplasty.

REFERENCES

1. Moosikasuwan JB, Thomas JM, Buchman TG. Myocardial infarction as a complication of injury. *J Am Coll Surg* 2000; 190: 665-70.
2. Chritensen MD, Nielsen PE, Sleight P. Prior blunt chest trauma may be a cause of single vessel coronary disease; hypothesis and review. *Int J Cardiol* 2006; 108: 1-5.
3. Yoon SJ, Kwon HM, Kim D and al. Acute myocardial infarction caused by coronary artery dissection following blunt chest trauma. *Yonsei Medical Journal* 2003; 44: 736-739.
4. Chun JH, Lee SC, Gwon HC and al. Left main coronary artery dissection after blunt chest trauma presented as acute anterior myocardial infarction: assessment by intravascular ultrasound: a case report. *J Korean Med Sci* 1998; 13: 325-7.
5. Park WS, Jeong MH, Hong YJ and al. A case of acute myocardial infarction after blunt chest trauma in a young man. *J Korean Med Sci* 2003; 18: 889-93.
6. Marcum JL, Booth DC and Sapin PM. Acute myocardial infarction caused by blunt chest trauma: successful treatment by direct coronary angioplasty. *American heart journal* 1996; 132: 1275-7.
7. Vincelj J, Sokol I, Samodol A and al. Acute myocardial infarction following blunt chest trauma due to sea traffic accident. *International Journal of cardiology* 2007; 121: 12-14.
8. Grozieux de Lagu renne, Pretorian EM, Jaboureck O and al. A case of chest trauma-induced acute myocardial infarction. *Annales de Cardiologie et d'Ang iologie* 2007; 56: 211-215.